

Case Report

Low Dose Spinal Anesthesia in Pregnant Patient with Eisenmenger Syndrome undergoing Caesarean Section

Anestesi Spinal Dosis Rendah pada Pasien Hamil dengan Sindrom Eisenmenger yang Menjalani Sectio Caesarea

Tommy M Tanuwijaya^{1*}, Tjahya Aryasa¹

¹Department of Anesthesiology and Intensive Therapy, General Hospital Prof Ngoerah Denpasar, Medical Faculty Udayana University
Jl. Diponegoro, Denpasar, Bali, 80113

*Corresponding author

Email: tommy.m.tanuwijaya@gmail.com

Received: June 13, 2023

Accepted: November 21, 2023

Abstract

Pregnancy with Eisenmenger syndrome is pregnancy with a high mortality rate and it is even recommended not to get pregnant based on the World Health Organization pregnancy risk. The aim of this paper is to present a choice of anesthetic techniques to facilitate pregnant patients with Eisenmenger syndrome undergoing caesarean section. A 25-year-old woman at 37 weeks' gestation came to the hospital with signs of labor accompanied by comorbid Eisenmenger syndrome. Caesarean section was facilitated with spinal anesthesia with bupivacaine heavy 0.5% 7.5 mg, fentanyl 25 mcg at level L2-L3 while loading 250 ml of crystalloid fluid and preparing norepinephrine drip. The patient's hemodynamics can be stabilized by titrating norepinephrine drip to 0.2 mcg/kg/minute and the patient's shortness of breath is gradually reduced. The patient was treated in intensive care for 2 days and was allowed to be outpatient after 5 days of being treated in the postnatal ward. Appropriate perioperative management can provide optimal results and is expected to prevent fatal perioperative events. As conclusion, low-dose spinal anesthetic techniques can be an option to facilitate caesarean section in pregnant patients with Eisenmenger syndrome.

Keywords: pregnancy; Eisenmenger syndrome; caesarean section; low dose spinal anesthesia

How to Cite:

Tanuwijaya TM, Aryasa T. Low dose spinal anesthesia in pregnant patient with Eisenmenger syndrome undergoing caesarean section. Journal of Medicine and Health. 2023; 6(1): 84-90. DOI: <https://doi.org/10.28932/jmh.v6i1.6704>

© 2023 The Authors. This work is licensed under a Creative Commons Attribution-NonCommercial 4.0 International License. 

Case Report

Abstrak

Kehamilan dengan sindrom Eisenmenger adalah kehamilan dengan tingkat mortalitas yang tinggi dan bahkan direkomendasikan untuk tidak hamil oleh berdasarkan *World Health Organization pregnancy risk*. Tujuan pembuatan laporan kasus ini adalah untuk mempresentasikan pilihan teknik anestesi untuk memfasilitasi pasien hamil dengan sindrom Eisenmenger yang menjalani sectio caesarea. Seorang wanita berumur 25 tahun dengan umur kehamilan 37 minggu datang ke rumah sakit dengan tanda-tanda hendak melahirkan dengan komorbid sindrom Eisenmenger. Sectio caesarea difasilitasi pembiusan blok spinal dengan regimen bupivacaine heavy 0.5% 7.5 mg dan fentanyl 25 mcg pada level L2-L3 dengan coloadung 250 mL cairan kristaloid serta mempersiapkan drip norepinefrin. Hemodinamik pasien dapat distabilkan dengan titrasi drip norepinefrin hingga 0,2 mcg/kg/menit dan keluhan sesak napas berangsur berkurang. Pasien dirawat di ruang intensif selama 2 hari dan diperbolehkan untuk rawat jalan setelah 5 hari dirawat di ruang rawat paska melahirkan. Manajemen perioperatif yang tepat dapat memberikan hasil yang optimal dan diharapkan dapat mencegah kejadian fatal perioperatif. Kesimpulannya adalah teknik anestesi spinal dosis rendah dapat menjadi pilihan untuk memfasilitasi tindakan sectio caesarea pasien hamil dengan sindrom Eisenmenger.

Kata kunci: kehamilan; sindrom Eisenmenger; sectio caesarea; anestesi blok spinal dosis rendah

Introduction

Incidence of congenital heart disease is recorded around 9 per 1000 births and more than 90% of these patients can survive to adulthood with improved medical technology and facilities. Congenital heart diseases such as ventricular septal defect (VSD), atrial septal defect (ASD), atrioventricular septal defect (AVSD), uncorrected patent ductus arteriosus (PDA) can evolve into Eisenmenger syndrome.¹ Pregnant women with Eisenmenger syndrome is a rare case with an incidence rate of around 3% and a high mortality rate of 30-50%. Crisis pulmonary hypertension, right heart failure, arrhythmias, and hypovolemia are the main causes of death in Eisenmenger syndrome patients with pregnancy. Eisenmenger syndrome is included in category IV of the World Health Organization (WHO) pregnancy risk which is recommended for not getting pregnant. Adverse events also occur in the fetus which has a high risk of spontaneous abortion, intrauterine growth restriction, preterm birth, low birth weight, and congenital heart disease.²⁻⁶

Anesthesia in pregnant patients with comorbid Eisenmenger syndrome who are planned for caesarean section is a challenge for anesthesiologists. Patients are expected to have no significant decrease in systemic vascular resistance (SVR) and no increase in pulmonary vascular resistance (PVR). The recommended choice of anesthesia technique is epidural anesthesia or combined spinal epidural anesthesia. In spite of these two anesthetic options, low dose spinal anesthesia can be an alternative and has been shown to reduce the effects of intraoperative hypotension.⁷⁻¹¹

Case Report

The purpose of this case report is to present a choice of anesthetic techniques to facilitate pregnant patients with Eisenmenger syndrome undergoing caesarean section. We present a case of caesarean section in a pregnant patient with Eisenmenger syndrome facilitated by low dose spinal anesthesia with optimal outcome.

Case

A 25 years old woman with a gestational age of 37 weeks came to Prof Ngoerah General Hospital with the main complaint of painful contractions accompanied by fluid leakage from the vagina 2 hours before entering the hospital. These complaints were accompanied by shortness of breath since 3 months of gestation. Initially the patient coughs and feels heavier breathing than before pregnancy. After these complaints appeared, the patient was more comfortable sleeping with 2 pillows. The patient was referred by the midwife to the Klungkung Hospital because the patient had severe shortness of breath before giving birth. The patient was known to have congenital heart disease after examination at the Klungkung Hospital and was referred to Prof Ngoerah General Hospital for further treatment. From the beginning of pregnancy, the patient only had a prenatal examination from the midwife. The patient admitted that she did not have shortness of breath or fainting after daily activities or sports since childhood. There was no history of surgery, drug or food allergies, or routine drug consumption.

From the preoperative physical examination, the patient weighed 43 kg, height 154 cm, looked cyanotic, blood pressure 106/70 mmHg, pulse 79 times per minute, heart sounds 1 and 2 single, regular, systolic murmur heard in the tricuspid area, respirations 24 times per minute, vesicular symmetrical breath sounds with no rhonchi and wheezing, SpO₂ measured 84% with room air and increased to 92-95% with oxygen supplementation 12 liters per minute via nonrebreathing face mask, no leg edema. Preoperative laboratory examination found Hb 13.4 g/dL with hematocrit 38.39% and platelets 198.0 x10³/μL. Blood gas analysis showed pH 7.45, pCO₂ 27 mmHg, pO₂ 71 mmHg, BE -5.2, HCO₃ 18.8 mmol/L, SaO₂ 95%, TCO₂ 19.6 mmol/L, Sodium 133 mmol/L, Potassium 3.1 mmol/L. The results of physiologic hemostasis, liver and kidney function were within normal limits. ECG results showed normal sinus rhythm, HR 84 beats per minute, right axis deviation, ST depression II, III, AVF, T Inverted V1-V5 (figure 1). The results of the patient's preoperative echocardiography were dilated RA-RV, LV concentric remodeling, EF BP 85%, TAPSE 1.9 cm; D-Shaped LV, severe TR with high probability of pulmonary hypertension, moderate pulmonal regurgitation, mPAP 48 mmHg, eRAP 3 mmHg, ASD secundum R-L shunt measuring 2.2 cm with a diagnosis of Eisenmenger syndrome (figure 2). The patient was concluded with physical status ASA IV E.

Case Report

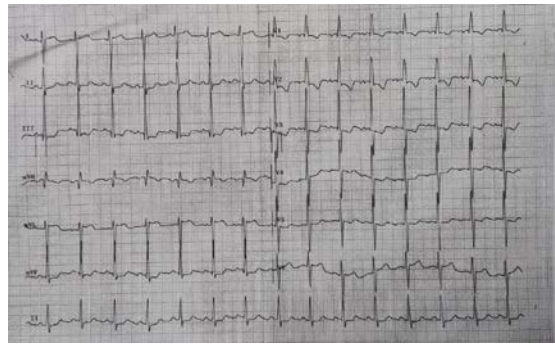


Figure 1 12-lead ECG

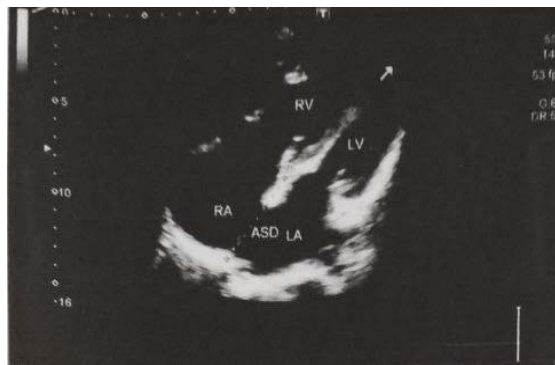

Figure 2 Transthoracic echocardiogram

After giving informed consent to the husband and family, the patient was prepared into the operating room. The infusion line is ensured to be smooth and a vital sign monitoring device is installed. The patient was anesthetized under spinal anesthesia with injection of bupivacaine heavy 0.5% 7.5 mg, fentanyl 25 mcg at level L2-L3 while loading 250 ml of crystalloid fluid and preparing norepinephrine drip. Baby girl weighing 2090 grams was born with APGAR score 8/9 and given oxytocin 20 units in RL 500 ml for 8 hours. The operation lasted 1 hour and 5 minutes. During surgery, the patient's hemodynamics could be stabilized by titrating norepinephrine drip to the highest value of 0.2 mcg/kg/minute and blood pressure fluctuations of 98-132/62-78 mmHg were achieved and the patient's shortness of breath gradually decreased. The patient was treated in the postoperative ICU for 2 days and was allowed to be outpatient after 5 days of treatment in the regular ward.

Discussion

Hemodynamic changes during pregnancy occur until postnatal period. The changed components are improved cardiac output about 50% with the highest peak in the second trimester as a result of increased intravascular volume and heart rate whereas SVR decreased by about 20% which is the effect of hormones. PVR also decreased but the pulmonary artery

Case Report

pressure did not change significantly due to an increase in pulmonary blood volume. These physiological changes are not well tolerated by Eisenmenger syndrome patients with the result that patients who are initially asymptomatic can appear symptoms such as fatigue and shortness of breath during light-to-moderate activities and orthopnea, even right heart failure. It also has an impact on the fetus. In Eisenmenger's syndrome, fixation of PVR and decreased SVR will aggravate right to left shunt as well as reduction functional residual capacity in the lungs which is a physiological change in respiration that begins in the fifth month of pregnancy causes these patients to have potential hypoxemia. Maternal hypoxemia will increase the incidence of fetal growth disorders until fetal death. Autotransfusion of uterine contractions postpartum can improve cardiac output approximately 25% resulting in an increase in pulmonary artery pressure and trigger heart failure and arrhythmias.^{3,7,12,13}

Anesthetic considerations in this patient are maintaining SVR, intravascular volume, preventing aortocaval compression, pain, hypoxemia, hypercarbia, and acidosis; therefore, pulmonary artery pressure does not increase and prevent myocardial depression. The recommended choice of anesthetic technique is epidural anesthesia or combined spinal epidural anesthesia rather than general anesthesia which is more risk of causing myocardial depression and decreased preload due to positive pressure ventilation. During the perioperative period, pulmonary hypertension can be treated by administering oxygen supplementation with a face mask and iloprost inhalation which is an analogue of prostacyclin with pulmonary vascular vasodilatory effect. Both of these can reduce PVR and correct hypoxemia.⁶⁻⁸ Oxytocin has an impact on hemodynamics, especially when given as a rapid bolus. Oxytocin can relax vascular smooth muscle tone, thereby creating the effect of reducing SVR and hypotension. Oxytocin also has receptors in the myocardium that can cause tachycardia. Tachycardia can increase PVR in patients with pulmonary hypertension.^{7,8,14-17}

Spinal anesthesia can cause hemodynamic disturbances such as hypotension, especially in pregnant patients. Low dose spinal anesthesia can reduce the hypotensive effect as proven by the research of Chandra et al. It can be an option to facilitate caesarean section in patients with cardiac disorders such as Eisenmenger syndrome.^{9-11,18,19} Hartono et al reported a similar case. Low dose spinal anesthesia with bupivacaine 0.5% 7.5 mg plus adjuvant fentanyl can stabilize hemodynamics until the end of surgery.²⁰

In this case, the patient had not been diagnosed with Eisenmenger syndrome prenatally, therefore cardiac problems and pulmonary hypertension were not treated during pregnancy. The patient was given supplemental oxygen via a nonrebreathing mask 12 liters per minute to improve oxygenation and reduce PVR. The patient was given a 250 ml loading of crystalloid fluid to maintain adequate intravascular volume prior to spinal anesthesia. Spinal anesthesia was

Case Report

performed with bupivacaine heavy 0.5% 7.5 mg with adjuvant fentanyl 25 mcg at level L2-L3. The result of anesthetic management in this patient was stable fluctuation in blood pressure and does not exacerbate shortness of breath or desaturation of the patient. During 2 days of treatment in the ICU, there were no signs of overload or heart failure so that the patient is transferred to the postnatal ward while continuing therapy from a cardiologist.

Conclusion

Pregnancy with Eisenmenger syndrome is a condition of pregnancy that has a high risk of mortality. Comprehensive treatment from the beginning of pregnancy is expected to reduce morbidity and mortality for both mother and fetus. Appropriate perioperative management can provide optimal results and is expected to prevent fatal perioperative events. Low-dose spinal anesthetic techniques can be an option to facilitate caesarean section in pregnant patients with Eisenmenger syndrome.

References

1. Baumgartner H, de Backer J, Babu-Narayan S V., Budts W, Chessa M, Diller GP, et al. 2020 ESC Guidelines for the management of adult congenital heart disease. *Eur Heart J* [Internet]. 2021;42(6):563–645.
2. Duan R, Xu X, Wang X, Yu H, You Y, Liu X, et al. Pregnancy outcome in women with Eisenmenger's syndrome: A case series from west China. *BMC Pregnancy Childbirth* [Internet]. 2016;16(1):1–8.
3. Yuan SM. Eisenmenger Syndrome in Pregnancy. *Braz J Cardiovasc Surg* [Internet]. 2016;31(4):325.
4. Gnanaraj JP, Princy A, Gnanaprakasam T, Balu K, Surendran A, Manimegalai E, et al. Maternal And Foetal Outcome in Eisenmenger Pregnancies: A Prospective Observational Study. *J Am Coll Cardiol*. 2022;79(9).
5. Katsurahgi S, Kamiya C, Yamanaka K, Neki R, Miyoshi T, Iwanaga N, et al. Maternal and fetal outcomes in pregnancy complicated with Eisenmenger syndrome. *Taiwan J Obstet Gynecol*. 2019;58(2):6597-602
6. Sliwa K, Baris L, Sinning C, Zengin-Sahm E, Gumbiene L, Yaseen IF, et al. Pregnant Women With Uncorrected Congenital Heart Disease: Heart Failure and Mortality. *JACC Heart Fail*. 2020;8(2):100-10
7. Vidovich MI. Cardiovascular Disease. In: Chestnut's Obstetric Anesthesia: Principles and Practice. Sixth edit. Philadelphia: Elsevier; 2020. p. 1001–3.
8. Tsen LC, Bateman BT. Anesthesia for Cesarean Delivery. In: Chestnut's obstetric anesthesia : principles and practice. Sixth edit. Philadelphia: Elsevier; 2020. p. 568–612.
9. Van De Velde M. Low-dose spinal anesthesia for cesarean section to prevent spinal-induced hypotension. *Curr Opin Anaesthesiol* [Internet]. 2019;32(3):268–70.
10. Abate S, Belihu A. Efficacy of low dose bupivacaine with intrathecal fentanyl for cesarean section on maternal hemodynamic: Systemic review and meta-analysis. *Saudi J Anaesth* [Internet]. 2019;13(4):340–51.
11. Almeida C, Vieira L, Cunha P, Gomes A. Low-dose spinal block combined with epidural volume extension in a high-risk cardiac patient: A case-based systematic literature review. *Saudi J Anaesth* [Internet]. 2022;16(4):383.
12. Niwa K. Adult Congenital Heart Disease with Pregnancy. *Korean Circ J* [Internet]. 2018;48(4):251–76.
13. Bishop L, Lansbury A, English K. Adult congenital heart disease and pregnancy. *BJA Educ* [Internet]. 2018;18(1):23.
14. Olsson KM, Channick R. Pregnancy in pulmonary arterial hypertension. *Eur Resp Rev* [Internet]. 2016;25(142):431–7.
15. Fernandes CJCS, da Silva TAF, Alves JL, Jardim CVP, de Souza R. Inhaled iloprost as third add-on therapy in idiopathic pulmonary arterial hypertension. *Pulm Circ*. 2021;11(1) :2045894020981350
16. Yildiz M, Kahraman S, Surgit O, Zencirkiran Agus H, Uygur B, Demir AR, et al. Acute effects of inhaled iloprost on intracardiac conduction in patients with pulmonary arterial hypertension. *Herz*. 2022;47(2):158-65
17. Slaibi A, Ibraheem B, Mohanna F. Challenging management of a pregnancy complicated by Eisenmenger syndrome; A case report. *Ann Med Surg*. 2021;16(69):102721
18. Liao Z, Xiong Y, Luo L. Low-dose spinal–epidural anesthesia for Caesarean section in a parturient with uncontrolled hyperthyroidism and thyrotoxic heart disease. *J Anesth*. 2016;30(4): 731-4
19. Chandra S, Nugroho AM, Agus H, Susilo AP. How low can we go? A double-blinded randomized controlled

Case Report

- trial to compare bupivacaine 5 mg and bupivacaine 7.5 mg for spinal anesthesia in cesarean delivery in Indonesian population. *Anesth Pain Med.* 2019;9(2):e91725
20. Hartono R, Ramadhani D, Isngadi I. Combination of low-dose spinal anesthesia and epidural anesthesia as anesthetic management in patient with uncorrected Double Outlet Right Ventricle (DORV) underwent cesarean section. *Ann Card Anaesth [Internet].* 2022;25(4):518–21.